

Perinatal survival following preferential sequential selective laser surgery for twin-twin transfusion syndrome

RAMEN H. CHMAIT¹, AMER KHAN¹, KURT BENIRSCHKE²,
DAVID MILLER¹, LISA M. KORST¹, & THOMAS M. GOODWIN¹

¹Division of Maternal-Fetal Medicine, Department of Obstetrics and Gynecology, Keck School of Medicine, University of Southern California, Los Angeles, California, USA, and ²Department of Pathology, University of California San Diego, San Diego, California, USA

(Received 30 December 2008; revised 13 June 2009; accepted 17 June 2009)

Abstract

Objective. To describe our experience with preferential use of sequential selective laser photocoagulation of communicating vessels (SQLPCV) in women with twin-twin transfusion syndrome (TTTS).

Methods. Women with TTTS received treatment using the SQLPCV technique whenever possible. SQLPCV mandates ablation of all donor-to-recipient arteriovenous communications first, in comparison to the standard non-sequential selective technique.

Results. Of 99 consecutive women treated, 64 received SQLPCV. Overall survival of one or both twins was 91% and dual survival was 72%. Higher dual survival rates (80 vs. 57%, $p = 0.0317$) and donor survival rates (83 vs. 63%, $p = 0.0489$) were noted in the SQLPCV group. Multivariable logistic regression demonstrated that the SQLPCV technique was highly associated with dual survivorship (OR = 4.64 [1.57–13.74], $p = 0.0056$), when controlling for gestational age at surgery, duration of laser treatment and number of anastomoses lasered. Neither Quintero stage, placental location, preoperative discordance prior to surgery, nor preoperative cervical length contributed to this equation. The SQLPCV technique was also associated with donor survivorship (OR = 4.43 [1.44–13.67], $p = 0.0095$), when controlling for the same covariates.

Conclusion. Treatment of TTTS via SQLPCV technique was associated with higher dual survival and donor twin survival rates as compared to standard SLPCV.

Keywords: Laser surgery, operative fetoscopy, twin-twin transfusion syndrome

Introduction

Twin-twin transfusion syndrome (TTTS) develops in monochorionic twins due to unbalanced sharing of blood through vascular communications in the common placenta [1,2]. Fetoscopic laser surgery treats TTTS by ablating the vascular communications. This approach is being used more regularly now, as recent studies demonstrate increased experience with the technique and the potential for therapeutic benefit with respect to perinatal survival and neurological outcome [3–9]. However, different centers performing laser surgery have reported survival rates for one or more fetuses ranging from 65 [10] to 91% [11].

Potential factors that may contribute to this variability in outcomes include the severity of TTTS, the degree of operability, the accuracy of placental mapping and the surgical technique employed.

Three surgical techniques have now been described in the literature. Reports from De Lia et al. [12] inferred and Ville et al. [13] described laser ablation of all vessels that cross the intertwin dividing membranes. Because this approach unnecessarily targets innocent vessels that do not connect the circulatory systems of the twins, it has been largely abandoned for the second, and currently standard technique, referred to as selective laser photocoagulation of communicating vessels (SLPCV) [14]. This

Correspondence: Ramen Chmait, Department of Obstetrics and Gynecology, Keck School of Medicine, University of Southern California, 1300 North Vermont Avenue, Suite 706, Los Angeles, California 90027, USA. Tel: +323-361-6074. Fax: +323-361-6099. E-mail: chmait@usc.edu
Previously presented: Preliminary results from this manuscript were presented in Abstract #516 at Poster Session IV, Society for Maternal-Fetal Medicine, 28th Annual Meeting, Dallas, Texas; February 1, 2008.

technique requires identification and ablation of only the vascular communications, which may in fact have absolutely no relationship to the location of the intertwin dividing membranes.

A third technique, the sequential SLPCV or SQLPCV, was recently described by Quintero et al. [11]. This technique mandates ablation of the vascular communications according to the following sequence: arteriovenous anastomoses from donor to recipient, arteriovenous anastomoses from recipient to donor, arterio-arterial superficial anastomoses and veno-venous superficial anastomoses. It is hypothesised that by performing the laser photocoagulation of the communicating vessels in this sequential fashion, development of intraoperative donor twin hypotension may be attenuated or prevented, thereby increasing the likelihood of donor twin survival [11]. Computer simulations of the SQLPCV technique support the concept of beneficial intraoperative transfusion from the hypervolemic recipient to the hypovolemic donor [15].

The ability to perform SQLPCV is dependent upon multiple intra-operative factors, and thus may not always be feasible. Visualisation and laser ablation of the vascular communications is dependent upon placental location, fetal position and clarity of the amniotic fluid. Consequently, during the course of surgery, it is possible that some of the communications may be treated out of the intended order, and thus the optimal fulfillment of the intention of the surgery may not be possible for all gestations.

Acknowledging the limitations of the application of this technique, in this study we describe our group's experience with SQLPCV, where it was the intended mode of treatment in all cases, given that it has a potential for benefit and does not appear to generate additional risk. Specifically, we examine the 28-day post-delivery survival rate and explore both gestational and surgical factors that may contribute to the choice of surgical technique and to perinatal outcomes.

Materials and methods

Our study population included all patients who underwent laser treatment for TTTS at our institution from March 2006 through March 2008. Patients referred to our institution underwent a comprehensive preoperative ultrasound examination. Mono-chorionic multiple gestations were diagnosed with TTTS if the maximum vertical pocket of amniotic fluid (MVP) was ≤ 2 cm in the donor's gestational sac and ≥ 8 cm in the recipient's sac. Disease severity was classified according to the Quintero staging system [16]. All patients diagnosed with TTTS between 16 and 26 weeks' gestation were offered laser surgery. Triplet pregnancies and patients with a short cervix were not excluded from participation.

All patients were counselled regarding management alternatives, which included expectant management, pregnancy termination, amnioreduction(s), laser surgery and umbilical cord occlusion of the sicker twin. Women who desired laser surgery gave written consent. All cases were performed percutaneously through a single port, with one insertion of the trocar. Maternal anesthesia was provided via local anesthesia with intravenous conscious sedation. The trocar was inserted into the sac of the polyhydramniotic recipient under direct ultrasound guidance. Transplacental trocar insertion was not performed. A 3.3-mm diagnostic endoscope (Richard Wolf, Vernon Hills, IL) was used to map the entire placental vascular equator. Each vascular communication was identified and labelled as an arteriovenous communication from donor-to-recipient (AVDR), from recipient-to-donor (AVRD) or superficial anastomoses such as arterio-arterial (AA) or veno-venous (VV). Whenever possible, the artery rather than the vein in AV anastomoses was ablated. After placental vascular mapping was completed, the vascular communications were photocoagulated using Nd:Yag laser energy at 20–40 W delivered into the amniotic cavity by 600 μm quartz non-contact fibres through the operating channel of the endoscope (Richard Wolf, Vernon Hills, IL). At the end of the surgery, amniotic fluid was removed until the maximum vertical pocket in the recipient's sac measured approximately 8 cm or less.

SQLPCV was attempted in all patients. The group of patients categorized as having SLPCV failed SQLPCV at some point during surgery when the sequential process could not be continued for technical reasons. Each case was categorized as having had SQLPCV *versus* SLPCV [17] immediately after surgery.

All patients were managed primarily by their obstetricians or maternal-fetal medicine specialists for the duration of their pregnancy and subsequent delivery. Persistent or recurrent TTTS was suspected if donor oligohydramnios (donor MVP ≤ 2 cm) and recipient polyhydramnios (recipient MVP ≥ 8 cm) persisted or recurred greater than 1 week after surgery. All patients were asked to ship their placentas fresh directly to the Pathology Department at the University of California, San Diego. The placentas were inspected by one of the authors (K.B.) independently of the other investigators. The pathologist was blinded to the type of laser surgery that was performed. Patency of vascular anastomoses was assessed via water and/or milk injections.

The main outcome measure of this study was postnatal survival. Survival was defined as a surviving neonate 28 days after birth. At least one twin survivor was defined as one or two survivors. Overall survival was defined as the total number of survivors divided by the total number of fetuses. The uninvolvement

triplet fetuses in cases of dichorionic triamniotic triplets were excluded from all analyses in regards to survival. Perinatal outcomes were obtained by acquiring copies of the medical records and/or by telephone interview of the referring providers and patients.

We describe both gestational and surgical characteristics of the study population by surgical technique used. Analyses were conducted using SAS version 9.1 (Cary, NC). All categorical data were analysed by Fisher's exact test or Chi-square test with Yates correction. Continuous data were compared non-parametrically using the Kruskal-Wallis test. A p -value of <0.05 was considered statistically significant. Multivariable logistic regression models were created to examine the relationship between surgical technique and outcome (dual survivor and donor survivor), adjusting for gestational age, stage, placental location, number of anastomoses, duration of laser treatment and pre-operative estimated fetal weight discordance. Odds ratios (OR) and 95% confidence intervals (CI) are provided. The study was approved by the Institutional Review Board at Health Sciences Campus of the University of Southern California, Los Angeles, California.

Results

During the study period, 101 women met criteria for TTTS, of whom 99 had laser surgery, 1 patient with Stage I TTTS elected pregnancy termination and 1 patient with Stage II TTTS opted for intentional septostomy of the dividing membranes that was performed at another centre. No patient underwent umbilical cord occlusion. Of the 99 consecutive patients who had laser surgery, 12 (12.1%) were stage I, 15 (15.2%) were stage II, 60 (60.6%) were stage III and 12 (12.1%) were stage IV. The overall mean (range) gestational age at time of laser surgery and delivery were 20.9 (16.1–26.7) and 32.4 (20.1–39.3) weeks, respectively.

For the entire study population, the 28-day postnatal survival of one or both twins was 90.9%, with a recipient and donor survival rate of 86.9 and 75.8%, respectively, and a dual survival rate of 71.7%. Of the 198 fetuses treated by laser therapy in this study, 161 (81.3%) were alive 28 days after birth.

Resolution of TTTS occurred in 98 of the 99 cases (99.0%). Recurrence or persistence of TTTS was diagnosed in one patient that had suboptimal visualisation of one area of the placenta due to ongoing bleeding and progressive amniotic fluid discoloration during the initial laser surgery. Persistent TTTS was confirmed 14 days later. The patent anastomoses were identified and photocoagulated during a second laser surgery, resulting in resolution

of the TTTS. No patient required intrauterine transfusion, amnioreduction or purposeful septostomy in the postoperative period.

SQLPCV was achieved in 64 of the 99 (64.6%) cases. Standard SLPCV was performed in 35 cases due to technical limitations. The reasons the non-sequential procedure was performed were as follows: the AVDR was identified and occluded after initial mapping and laser ablation of the other anastomoses in 13 cases, the placenta was scalloped in three cases [18], amniotic fluid was discolored in six cases, the donor twin was shielding the vascular equator in five cases, the anastomoses were deep in the donor's territory in three cases, placental location precluded access in three cases, free floating dividing membranes from a prior septostomy reduced visualisation in one case and patient discomfort in one case. Among those who received the non-sequential procedure, no measure of survival was associated with the technical reason for the failure, percent of vessels lasered nonsequentially and duration of laser treatment (data not shown).

Preoperative and operative characteristics of patients that underwent SLPCV versus SQLPCV are shown in Table I. Univariately, there were no differences between the two groups in the Quintero stage, maximum vertical pockets of amniotic fluid in the donor or recipient sacs, amnioreductions performed prior to laser, triplet gestations, cervical length, requirement for cervical cerclage or twin weight discordance before surgery. Patients in the standard SLPCV group were nearly twice as likely to have an anterior placenta (54.3 *vs.* 29.7%, relative risk: 1.83 [95% CI: 1.13–2.97], $p=0.0285$). These patients also had an increased mean operative time in minutes (SD) compared to the SQLPCV group (60.4 [27.4] *vs.* 45.4 [15.2], $p=0.0066$) and had a slightly higher gestational age in weeks at the time of surgery: 21.6 (2.6) *vs.* 20.5 (2.3), $p=0.0485$. The number of anastomoses lasered (SD) was equivalent in the two groups: 7.7 (3.2) (median: 7, range: 3–16) *vs.* 7.7 (3.9) (median: 7, range: 1–21), $p=0.7940$. Among patients in the SLPCV group, the mean percent of anastomoses (SD) that were non-sequentially lasered was 33.0% (15.4%) (median: 33.0%, range: 10.0–62.5%).

To determine if there were any differences in patient or operative characteristics associated with gaining surgical expertise over time, a stratified analysis was conducted, separating patients into 'early' and 'late' cases by the median date. The proportion of cases that were in the sequential group was equivalent across the two time periods: 45.3% (early) *vs.* 54.7% (late), $p=0.2352$. There was no statistical difference in survival rates over time. Of the early cases, 92.0% had at least one survivor compared to 89.8% of the late cases ($p=0.9746$); of

Table I. Preoperative and operative characteristics of each surgical group.

	Non-sequential (35)	Sequential (64)	<i>p</i>
Mean (SD) GA at surgery (weeks)	21.6 (2.6)	20.5 (2.3)	<0.05
Quintero Stage I	5 (13.4%)	7 (11.1%)	0.26
Quintero Stage II	7 (19.4%)	8 (12.7%)	
Quintero Stage III	20 (57.1%)	40 (62.5%)	
Quintero Stage IV	3 (8.3%)	9 (14.3%)	
Mean (SD) recipient MVP (cm)	11.8 (2.6)	11.6 (2.6)	0.68
Mean (SD) donor MVP (cm)	1.0 (1.2)	0.9 (1.3)	0.69
Prior amnioreduction	3 (8.6%)	6 (9.4%)	1.00
Triples	2 (5.7%)	4 (6.3%)	1.00
Mean (SD) operative time (min)	60.4 (27.4)	45.4 (15.2)	0.01
Mean (SD) laser treatment time (min)	34.3 (19.8)	27.0 (14.2)	0.10
Mean (SD) number of anastomoses lasered	7.7 (3.2)	7.9 (3.9)	0.93
Anterior placenta	19 (54.3%)	19 (29.7%)	0.03
Mean (SD) cervical length (cm)	3.5 (1.1)	3.4 (1.0)	0.67
Cerclage	1 (2.9)	1 (1.6)	1.00
Twin discordance before surgery	25.7% (12.9%)	27.8% (13.9%)	0.43
Mean (SD) EFW donor (g)	341 (161)	291 (134)	0.13
Mean (SD) EFW recipient (g)	457 (193)	409 (182)	0.25

SD, standard deviation; GA, gestational age; MVP, maximum vertical pocket of amniotic fluid.

the early cases, 68.0% had dual survivors compared with 75.5% of the late cases ($p = 0.5443$).

Neonatal survival at 28 days after birth according to surgical method utilised for the treatment of TTTS is shown in Figure 1. The patients in the SQLPCV group had a significantly higher rate of dual survival at 28 days after birth *versus* the standard SLPCV group (79.7 *vs.* 57.1%, $p = 0.0317$). This finding was largely due to the increased rate of donor twin survival in the SQLPCV group compared to the standard SLPCV group (82.8 *vs.* 62.9%, $p = 0.0489$). Fifty-two of 70 fetuses (74.3%) survived in the standard SLPCV group, compared with 109 of 128 (85.2%) total survivors in the SQLPCV group ($p = 0.0919$). The birth weights of both the recipients and the donors were significantly higher in the SQLPCV group (Table II).

A subanalysis that only included the 72 patients with Quintero Stage 3 or Stage 4 TTTS was conducted. The survival data for the SLPCV *vs.* the SQLPCV were as follows: (1) at least one fetus survived: 95.7 *vs.* 91.8% ($p = 0.9230$), (2) both fetuses survived: 47.8 *vs.* 77.6% ($p = 0.0244$), donor survival: 56.5 *vs.* 81.6% ($p = 0.0491$) and recipient survival: 87.8 *vs.* 87.0% ($p = 1.0000$).

Multivariable logistic regression modeling demonstrated that the SQLPCV technique was highly associated with dual survivorship (OR = 4.64 [1.57–13.74], $p = 0.0056$), when controlling for gestational age in weeks at time of surgery (OR = 1.44 [1.12–1.86], $p = 0.0046$), duration of laser treatment in 10 minute increments (OR = 0.66 [0.48–0.92], $p = 0.0131$), and the number of anastomoses lasered (OR = 1.19 [1.01–1.39], $p = 0.0328$). Neither Quintero stage, placental location, preoperative discordance prior to surgery, nor preoperative cervical

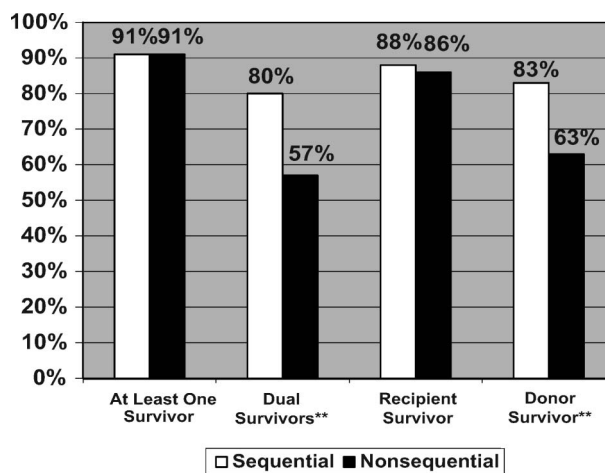


Figure 1. Comparison of 28-day perinatal survival according to selective laser technique. **Significant difference noted in survival between the two groups ($p < 0.05$).

length contributed to this equation. The SQLPCV technique was also associated with donor survivorship (OR = 4.43 [1.44–13.67], $p = 0.0095$), when controlling for the same covariates.

Seventy-three of the 99 patients submitted their placentas for pathologic evaluation: 47 placentas were from cases that underwent SQLPCV and 26 were from SLPCV cases. Analysis of the 53 placentas from dual fetal survivors revealed patent anastomoses in 2 (3.8%) placentas, which were split evenly between the two groups.

Discussion

Previous research regarding therapy for TTTS has focussed on the comparison of laser surgery to other

Table II. Pregnancy outcomes according to the surgical method.

	Non-sequential (36)	Sequential (63)	<i>p</i>
Mean (SD) GA delivery (weeks)	31.6 (4.3)	32.8 (4.7)	0.06
Cesarean section delivery	25 (71.4%)	48 (75.0%)	0.88
At least one survivor	32 (91.4%)	58 (90.6%)	1.00
Dual survivors	20 (57.1%)	51 (79.7%)	0.03
Recipient survivor	30 (85.7%)	56 (87.5%)	1.00
Donor survivor	22 (62.9%)	53 (82.8%)	<0.05
Mean (SD) recipient birth weight (g)	<i>N</i> = 31, 1674 (662)	<i>N</i> = 56, 1981 (630)	0.02
Mean (SD) donor birth weight (g)	<i>N</i> = 27, 1330 (727)	<i>N</i> = 55, 1710 (681)	0.02

SD, standard deviation; GA, gestational age; survivor, neonate alive 28-days after birth.

treatment modalities, namely serial amnioreductions. The preponderance of data, which was presented recently in a metaanalysis and review of literature, have shown that laser surgery is the optimal treatment for TTTS [19]. In that review, laser therapy was associated with 75–87% survival for at least one twin and 57–77% for overall survival [19]. The results of our study compared favourably, with an at least one survivor rate of 91% and overall survival rate of 81%.

Now that there is a growing consensus that laser therapy appears to be the treatment of choice for TTTS diagnosed between 16 and 26 weeks' gestation, the next step is to determine the optimal surgical approach. Quintero et al. [11] recently reported on a modification of their original SLPCV technique, called sequential SLPCV (SQLPCV). SQLPCV specifically requires that all arteriovenous anastomoses from the donor to the recipient (AVDR) must be ablated first. That study compared perinatal outcomes in TTTS cases treated by standard SLPCV versus SQLPCV. The donor fetal demise rate was lower and the dual twin survival rate was higher in the sequential laser group. It was hypothesised that SQLPCV may improve intraoperative donor twin hemodynamics, resulting in an overall donor twin survival advantage [11].

Here, we describe our efforts to treat all eligible candidates for laser surgery for TTTS by the sequential procedure. Among those patients who received the full benefit of the SQLPCV technique, the rate of donor twin survival at 28 days of life was 83% compared to only 63% in those cases where it could not be used as intended. This technique was also associated with a higher dual twin survival, as shown in Figure 1. These findings were consistent with those reported by Quintero et al. [11].

Because of our efforts to treat all patients with the sequential technique, we cannot attribute the increased survival rates to the technique itself. The cases that failed the sequential procedure had a higher prevalence of anterior placentas and somewhat longer operative times. This suggests that surgical cases that underwent the standard technique

may have been more complex. How this complexity might itself be associated with a poorer donor twin survival is not entirely clear, and it is not elucidated by the variety of reasons encountered for failure.

The SQLPCV surgical approach is both an anatomical and functional treatment of TTTS [11]. The end result of standard *versus* sequential SLPCV is the same; the placenta is 'dichorionized' to render the circulatory systems of the twins independent. However, the SQLPCV laser technique may allow for intraoperative shunting of blood towards the donor fetus, or at the very least, decrease or prevent intraoperative depletion of donor blood volume. This surgical manoeuvre may be beneficial for the donor fetus suffering from hypovolemia. Prior studies suggest that hypovolemia in the donor twin is an important clinical manifestation of TTTS. Indeed, the donor fetus has been shown to have significant up-regulation of the renin-angiotensin system and increased vasopressin levels [20,21]. Pathologic evaluation of the donor's kidneys has identified renal tubular dysgenesis, a suggested marker for chronic renal hypoperfusion [20]. The increased need for postnatal vasopressor and inotropic support also suggests that the donor fetus may be especially vulnerable to hypotension [22]. It is conceivable that the intraoperative hemodynamic fluxes may be blunted by the SQLPCV technique, resulting in relatively decreased risk of postoperative donor demise.

Van Gemert et al. [15] recently used a computer model to investigate this theory. They simulated an equally shared placenta with an AVDR and a smaller diameter AVR causing TTTS at 20 weeks. They then simulated laser coagulation and various volumes and directions of inter-twin transfusion at 21 weeks, citing a typical result: when an AVDR is coagulated first, and 10 min later the AVR with an inner diameter of about 1 mm is coagulated, an inter-twin transfusion of 25 ml may result from the recipient to the donor, based on literature data of AV flow versus diameter. The sequential procedure would cause a simulated loss of 50% of the

recipient's blood volume. The opposite coagulation sequence would cause a loss of the donor's blood volume of 64%. These results support the hypothesis behind the use of the sequential procedure.

To perform the SQLPCV technique, the anastomoses must be catalogued prior to initiation of laser ablation so that the AVDR's can be ablated first. Both standard and sequential SLPCV require selective ablation of only the vascular communications. In the standard SLPCV approach, the surgeon ablates the vascular communications from one end of the placenta to the other. The sequence of vessels ablated is dictated by the placental vascular anatomy particular to each case. The SQLPCV technique requires more than one pass across the vascular equator to ablate the AVDR's first, AVRDR's second, followed by the AA's and VV's. The extra effort to target each type of Anastomosis is usually minimal. In this study, SQLPCV was able to be performed in 65% of the cases, with the others receiving standard SLPCV. Thirty-seven percent of the cases in the standard SLPCV group were performed out of sequence because an AVDR was discovered and ablated after the other communications were occluded. The majority of the remaining cases were non-sequential because of suboptimal visibility of the vascular communications due to a variety of case-specific issues such as placental anatomy, amniotic fluid discolouration, or relationship of the vascular communications to the donor fetus' position. In these cases, the ability to perform multiple passes across the placenta was hampered by these technical issues.

Regardless of the surgical technique performed, the fundamental goal of laser therapy is to functionally create a dichorionic placenta from a monochorionic placenta. It has been argued that consistent achievement of this goal is not feasible [23]. Supporting this, one study showed that the rate of patent anastomoses after laser surgery was as high as 33% [24]. Another study reported a 10% rate of TTTS recurrence [23]. In contrast, we found that functional dichorionicity was attainable in the vast majority of cases using surgical techniques that have been described previously [25,26]. The rate of recurrence or persistence of TTTS was 1%, and the rate of patent anastomoses was less than 4%. It is important to note that, regardless of severity of disease or technical complexity of a particular case, no patient underwent umbilical cord occlusion. Our ability to create a functionally dichorionic placenta in nearly all laser cases for TTTS may be one explanation for the overall favourable perinatal outcomes in this study.

In conclusion, our experience with SQLPCV demonstrates high rates of survival overall and in particular for donor twins. However, whether this

survival advantage can be attributed to the sequential technique cannot be directly demonstrated by this study design. A multi-centre randomised trial is being organised to compare perinatal outcomes in cases of TTTS treated by standard *versus* sequential SLPCV.

Acknowledgements

The authors would like to acknowledge Terri Maitino, R.N. for obtaining the outcome data used in this study, and Larisa Yedigiarova, M.D., Ph.D., for her oversight of the protocol with the local investigational review board.

References

1. Quintero R, Quintero L, Bornick P, Allen M, Johnson P. The donor-recipient (D-R) score: *in vivo* endoscopic evidence to support the hypothesis of a net transfer of blood from donor to recipient in twin-twin transfusion syndrome. *Prenat Neonat Med* 2000;5:84-91.
2. Bajoria R, Wigglesworth J, Fisk NM. Angioarchitecture of monochorionic placentas in relation to the twin-twin transfusion syndrome [see comments]. *Am J Obstet Gynecol* 1995; 172:856-863.
3. Middeldorp JM, Sueters M, Lopriore E, Klumper FJ, Oepkes D, Devlieger R, Kanhai HH, Vandenbussche FP. Fetoscopic laser surgery in 100 pregnancies with severe twin-to-twin transfusion syndrome in the Netherlands. *Fetal Diagn Ther* 2007;22:190-194.
4. Ierullo AM, Papageorghiou AT, Bhide A, Fratelli N, Thilaganathan B. Severe twin-twin transfusion syndrome: outcome after fetoscopic laser ablation of the placental vascular equator. *BJOG* 2007;114:689-693.
5. Huber A, Diehl W, Bregenzer T, Hackeloer BJ, Hecher K. Stage-related outcome in twin-twin transfusion syndrome treated by fetoscopic laser coagulation. *Obstet Gynecol* 2006; 108:333-337.
6. Senat MV, Deprest J, Boulvain M, Paupe A, Winer N, Ville Y. Endoscopic laser surgery versus serial amnioreduction for severe twin-to-twin transfusion syndrome. *N Engl J Med* 2004;351:136-144.
7. Quintero RA, Dickinson JE, Morales WJ, Bornick PW, Bermudez C, Cincotta R, Chan FY, Allen MH. Stage-based treatment of twin-twin transfusion syndrome. *Am J Obstet Gynecol* 2003;188:1333-1340.
8. Graef C, Ellenrieder B, Hecher K, Hackeloer BJ, Huber A, Bartmann P. Long-term neurodevelopmental outcome of 167 children after intrauterine laser treatment for severe twin-twin transfusion syndrome. *Am J Obstet Gynecol* 2006;194:303-308.
9. Banek CS, Hecher K, Hackeloer BJ, Bartmann P. Long-term neurodevelopmental outcome after intrauterine laser treatment for severe twin-twin transfusion syndrome. *Am J Obstet Gynecol* 2003;188:876-880.
10. Crombleholme TM, Shera D, Lee H, Johnson M, D'Alton M, Porter F, Chyu J, Silver R, Abuhamad A, Saade G, et al. A prospective, randomized, multicenter trial of amnioreduction vs selective fetoscopic laser photocoagulation for the treatment of severe twin-twin transfusion syndrome. *Am J Obstet Gynecol* 2007;197:e391-e399.
11. Quintero RA, Ishii K, Chmait RH, Bornick PW, Allen MH, Kontopoulos EV. Sequential selective laser photocoagulation of communicating vessels in twin-twin transfusion syndrome. *J Matern Fetal Neonatal Med* 2007;20:763-768.

12. De Lia JE, Kuhlmann RS, Harstad TW, Cruikshank DP. Fetoscopic laser ablation of placental vessels in severe previabile twin-twin transfusion syndrome. *Am J Obstet Gynecol* 1995;172:1202–1208; discussion 1208–1211.
13. Ville Y, Hyett J, Hecher K, Nicolaides K. Preliminary experience with endoscopic laser surgery for severe twin-twin transfusion syndrome. *N Engl J Med* 1995;332:224–227.
14. Quintero R, Morales W, Mendoza G, Allen M, Kalter CS, Giannina G, Angel JL. Selective photocoagulation of placental vessels in twin-twin transfusion syndrome: evolution of a surgical technique. *Obstet Gynecol Surv* 1998;53:s97–s103.
15. Van Gemert MJC, van den Wijngaard JPHM, Lopriore BE, Lewid L, Deprest J, Vandenbussche FPH. Simulated sequential laser therapy of twin-twin transfusion syndrome. *Placenta* 2008;29:609–613.
16. Quintero R, Morales W, Allen M, Bornick P, Johnson P, Krueger M. Staging of twin-twin transfusion syndrome. *J Perinatol* 1999;19:550–555.
17. Quintero RA, Comas C, Bornick PW, Allen MH, Kruger M. Selective versus non-selective laser photocoagulation of placental vessels in twin-twin transfusion syndrome. *Ultrasound Obstet Gynecol* 2000;16:230–236.
18. Chmait RH, Rossi AC, Quintero RA. Paradoxical scalloped placenta with polyhydramnios in twin-twin transfusion syndrome. *J Matern Fetal Neonatal Med* 2007;20:29–32.
19. Rossi AC, D'Addario V. Laser therapy and serial amnioreduction as treatment for twin-twin transfusion syndrome: a metaanalysis and review of literature. *Am J Obstet Gynecol* 2008;198:147–152.
20. Mahieu-Caputo D, Meulemans A, Martinovic J, Gubler MC, Delezoide AL, Muller F, Madelenat P, Fisk NM, Dommerques M. Paradoxical activation of the renin-angiotensin system in twin-twin transfusion syndrome: an explanation for cardiovascular disturbances in the recipient. *Pediatr Res* 2005;58:685–688.
21. Bajoria R, Ward S, Sooranna SR. Influence of vasopressin in the pathogenesis of oligohydramnios-polyhydramnios in monochorionic twins. *Eur J Obstet Gynecol Reprod Biol* 2004;113:49–55.
22. Lopriore E, Nagel HT, Vandenbussche FP, Walther FJ. Long-term neurodevelopmental outcome in twin-to-twin transfusion syndrome. *Am J Obstet Gynecol* 2003;189:1314–1319.
23. Stirnemann JJ, Nasr B, Quarello E, Ortquist L, Nassar M, Bernard JP, Ville Y. A definition of selectivity in laser coagulation of chorionic plate anastomoses in twin-to-twin transfusion syndrome and its relationship to perinatal outcome. *Am J Obstet Gynecol* 2008;198:62 e61–e66.
24. Lopriore E, Middeldorp JM, Oepkes D, Klumper FJ, Walther FJ, Vandenbussche FP. Residual anastomoses after fetoscopic laser surgery in twin-to-twin transfusion syndrome: frequency, associated risks and outcome. *Placenta* 2007;28:204–208.
25. Quintero RA, Bornick PW, Allen MH, Johnson PK. Selective laser photocoagulation of communicating vessels in severe twin-twin transfusion syndrome in women with an anterior placenta. *Obstet Gynecol* 2001;97:477–481.
26. Quintero R. Selective laser photocoagulation of communicating vessels. In: Quintero R, editor. *Diagnostic and operative fetoscopy*. New York: The Parthenon Publishing Group; 2002. pp 52–53.